*Environmental Health Perspectives*
*101(Suppl 5): 121–124 (1993)*

# Cell Proliferation and Nasal Carcinogenesis

## by Thomas M. Monticello,[1,2] Elizabeth A. Gross,[1] and Kevin T. Morgan[1]

**The nasal passages of rodents provide valuable opportunities for research on relationships between cell proliferation and cancer. The nose, which has multiple functions, possesses a diverse range of tissue types, each with its own morphologic, physiologic, and metabolic characteristics and site-specific cell turnover rates. Moreover, for inhaled materials deposited in the nose, complex regional uptake or deposition patterns can result in site-specific responses, including cancer. Presented here are important criteria necessary for undertaking cell proliferation studies in the nasal passages. The current literature concerning nasal toxicity and the toxicant-induced proliferative response are also reviewed. Rodent nasal epithelium provides a fruitful area for research on the role of cell proliferation in carcinogenesis.**

## Introduction

The nasal passages have multiple functions including important roles in protecting the lower respiratory airways by absorbing water-soluble gases and vapors, clearing inhaled particles, and metabolizing inhaled xenobiotics. As the portal of entry for the respiratory tract, the nose is a prime site for chemically induced pathology. Epithelial regeneration and adaption (e.g., squamous metaplasia) are common responses of the nasal epithelium after toxic insult. By replacing and adapting the epithelial barrier, these proliferative events act to repair damaged epithelium and to protect the airway mucosa from further insult. The epithelium lining the upper respiratory tract, including the nasal passages, is normally in a steady state of cell renewal, in which cell production balances cell loss (*1*). Under these conditions, the cell turnover time for the respiratory epithelium is long (*2*). Increases in cell proliferation are seen in chronically irritated airway epithelium, however, which is also a common site for malignant transformation (*3*). Epithelial proliferation in response to irritation is best exemplified by cigarette smoke-induced bronchial metaplasia, hyperplasia, dysplasia, and carcinoma (*4*).

Cell kinetic studies combined with histopathology may provide valuable information on the biology of both neoplastic and nonneoplastic tissue responses to toxic chemicals. In some instances, alterations in cell proliferation are a more sensitive indicator of respiratory cell injury than routine histopathological evaluation (*5*). This paper addresses important criteria necessary for undertaking cell proliferation studies in upper respiratory tract tissues, with special emphasis on the nasal passages. Also, the current literature is briefly reviewed regarding the potential association of toxicant-induced alterations in cell proliferation with nasal toxicity and cancer.

## Nasal Cell Proliferation Studies

The rodent nasal passages are complex (Fig. 1) and include a variety of site-specific epithelial types, including squamous, cuboidal-transitional, respiratory, and olfactory, each with its own background cell turnover rates. Both chemically induced neoplastic and nonneoplastic lesions in the rat nose vary considerably in location and nature, which is attributed to regional differences in deposition, tissue susceptibility, or metabolism (*6*). Due to the site specificity of toxicant-induced lesions and the site-specific morphological variation in nasal epithelium, a systematic histological examination of the nasal passages is necessary before assessing cell proliferation.

There are many approaches available for assessing cell kinetics in tissue. For solid parenchymal organs, such as the liver, cell proliferation data are routinely

[1]Chemical Industry Institute of Toxicology, Research Triangle Park, NC 27709.
[2]Current address: Pharmaceutical Research Institute, Bristol-Myers Squibb, Princeton, NJ 08543.
Address reprint requests to Information Services, CIIT, P.O. Box 12137, Research Triangle Park, NC 27709.
This paper was presented at the Symposium on Cell Proliferation and Chemical Carcinogenesis that was held January 14–16, 1992, in Research Triangle Park, NC.

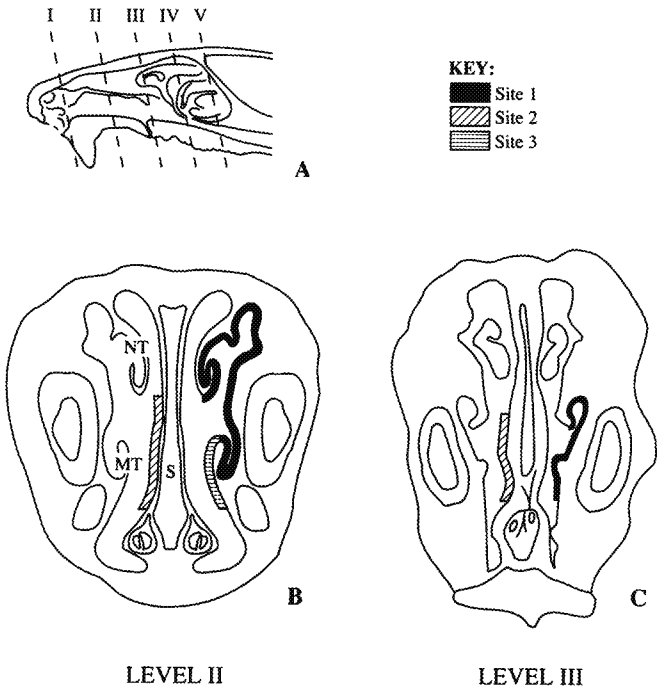


FIGURE 1. Lateral view (*A*) of the rat nose showing turbinates and location of levels (I–V), demonstrating the complexity of the nasal passages and sites selected for recent cell proliferation studies (*5*). (*B*) Cross-section at level II, (*C*) cross-section at level III. The majority of formaldehyde-induced squamous cell carcinomas originated at sites 1 and 2 (*23*). The nasal cell proliferation response following formaldehyde exposure, however, occurs equally in sites 1, 2, and 3. Reprinted with permission (*5*).

expressed as a percentage of labeled cells divided by the total or a representative subtotal cell population under study (i.e., a labeling index; LI). Special considerations may be warranted, however, when determining the proportion of cells undergoing replicative DNA synthesis in nasal epithelia. Determining cell LI in the epithelium lining the nasal passages can be very labor intensive due to the extensive surface area and the large number of cells that must be quantified. This effort could be reduced by selection of specific areas, based on histopathology, which may also result in the collection of more meaningful data. Another important concern is alterations in total cell population in response to treatment, either through cell loss (cytotoxicity and exfoliation) or cell increase (hyperplasia), both of which may influence the LI. If such changes occur in a nondividing population of the epithelium (e.g., ciliated respiratory epithelial cells, mature olfactory sensory cells) in the absence of a true proliferative response in the cells capable of replicative DNA synthesis (e.g., basal and/or secretory cells), an apparent increase in the LI may occur simply because the denominator for the LI calculation has changed (*7*). An alternative method, which expresses cell proliferation data as the number of labeled cell profiles per surface area (unit length labeling index; ULLI), has been described (*7*). This method is less labor intensive than obtaining LI and has been shown to be a more appropriate method in certain situations where cell loss influences the calculation of LI (*7*). Moreover, the ULLI method considers and adjusts for cellular and nuclear hypertrophy, both of which have the potential to influence cell proliferation data (*8*).

## Proliferative Responses to Nasal Carcinogens

A number of chemicals induce neoplasms in the nasal cavity of the rat, but quantitative information characterizing proliferative responses of the nasal epithelium to carcinogens is minimal (*9*). The tobacco-specific nitrosamine 4-(*N*-methyl-*N*-nitrosamino)-1-(3-pyridyl)-1-butanone (NNK) is a rat nasal carcinogen (*10*). Molecular dosimetry studies of NNK have demonstrated that the promutagenic adduct $O^6$-methyl deoxyguanosine ($O^6$MG) forms in both the respiratory and olfactory rat nasal mucosa (*11*). Nasal tumors induced by NNK, however, arise primarily from the olfactory region of the nose, either from the olfactory epithelium or underlying Bowman's glands, in association with extensive cytotoxicity, necrosis, and basal cell hyperplasia and metaplasia (*11*). In contrast, NNK-induced lesions in nasal respiratory epithelium are mild (*11*). The investigators concluded that an increase in cell proliferation of the olfactory epithelium, evidenced qualitatively as basal cell hyperplasia and metaplasia, coupled with the formation of promutagenic adducts at this site, were required for the induction of olfactory tumors by NNK (*11*).

A more quantitative correlation between cell proliferation and cancer has been investigated for another rodent nasal carcinogen, the nongenotoxicant 1,4-dioxane[dioxane (*12*)]. Dioxane, a colorless liquid used as a specialty solvent, induces nasal squamous cell carcinomas in rats when administered for 2 years in drinking water (*13*). Tumor mapping data revealed that these dioxane-induced nasal squamous cell carcinomas arose primarily in the nasal septum or nasoturbinate of the anterior portion of the dorsal medial meatus (*12*). These sites were selected for subsequent cell proliferation studies after acute administration of dioxane under bioassay conditions (*12*). After 2 weeks of administration, no histological lesions or increases in LI over age-matched controls were observed at the nasal sites studied. It was concluded that either chronic administration of dioxane is necessary before proliferative responses are seen, or that mechanisms other than cell proliferation might be involved in dioxane-induced nasal cancer (*12*).

Another short-term nasal cell proliferation study has been reported recently that examined the proliferative and cytotoxic effects of the oral analgesic drug phenacetin, a rodent nasal carcinogen (*14*). Dietary administration of phenacetin to rats at a concentration of 1.25 or 2.5% results in squamous or transitional cell

carcinomas or adenocarcinomas of the nasal cavity (*15*). In the cell proliferation study, rats were administered phenacetin in feed for 1–2 weeks, at levels similar to those reported in the oncogenicity study. After 1 week of administration, [$^3$H]thymidine incorporation in DNA of the nasal mucosal cells was measured biochemically. Phenacetin induced a dose-related increase in DNA synthesis in both the respiratory and olfactory mucosae. However, the increase in DNA synthesis of the respiratory mucosa was due to an infiltration of labeled inflammatory cells and not to proliferation of the surface respiratory cells (*14*). This finding demonstrates the importance of histopathological evaluation when undertaking investigative cell proliferation studies.

Histoautoradiography studies performed in rats administered phenacetin for up to 2 weeks revealed degenerative changes in the olfactory epithelium in addition to necrosis of the underlying Bowman's glands (*14*). These lesions were associated with increases in cell proliferation only in the olfactory epithelium. A clear dose-response relationship for cell proliferation was detected that also correlated with the reported tumor response from the chronic study (*14*). The authors concluded that early proliferative responses may be important in the induction of nasal tumors seen with phenacetin (*14*). Moreover, it was suggested that cell proliferation studies could provide important data that may be useful for setting dose levels in chronic bioassays.

For the above studies, each chemical was administered orally or parenterally. There are few inhalation studies where nasal cell proliferation was also evaluated. Preliminary inhalation studies with gluteraldehyde, a respiratory tract irritant and cross-linking agent, were recently reported (*16*). The evaluation of nasal tissues from acute and subchronic exposures demonstrated that gluteraldehyde-induced lesions in rats and mice were confined to the most anterior portion of the nasal passages and consisted of erosions, squamous hyperplasia, and inflammation. The nasal lesions were associated with significant, concentration-dependent increases in cell proliferation. Concentration-dependent nasal lesions and increases in cell proliferation were also reported for an intranasal instillation study with glutaraldehyde (*17*), which demonstrated that this aldehyde was an order of magnitude more toxic to nasal epithelium than formaldehyde, a known rat nasal carcinogen (*18*). Cell proliferation data obtained from these glutaraldehyde studies will be of value for selecting exposure concentrations in the chronic bioassay.

## Formaldehyde-Induced Cell Proliferation

To date, the most extensive database on nasal cell proliferation was assembled from a chronic formaldehyde pathogenesis study in the F344 rat (*8*). Formaldehyde is weakly mutagenic, binds covalently *in vitro* to DNA and associated proteins, and reacts preferentially with single-stranded DNA (*19*). Formaldehyde-induced elevations in nasal cell proliferation may, therefore, have special relevance in the carcinogenic process. Recent studies have shown that formaldehyde-induced nasal lesions and increases in cell proliferation after acute (1, 4, 9 days or 6 weeks) or subchronic (3-month) exposure are concentration dependent and occur in specific regions of the anterior nasal passages, primarily the walls of the lateral meatus, septum adjacent to the middle meatus, and medial aspect of the maxilloturbinate (*5,20*). The increases in cell proliferation were associated with nasal lesions, including degeneration, necrosis, hyperplasia, and squamous metaplasia. After 4 days or 6 weeks of exposure, an increased LI was observed in rats exposed to either 6, 10, or 15 ppm formaldehyde, whereas no increases were detected in the 0.7 or 2 ppm groups (*5*). After 3 months of exposure, however, increases in cell proliferation were confined to only the two highest exposure concentrations, 10 and 15 ppm (9). These results demonstrate that 0.7 and 2 ppm formaldehyde does not induce increases in nasal cell proliferation and that 6 ppm induces transient increases that return to control levels by 3 months. The early transient increase in cell proliferation observed at 6 ppm emphasizes the importance of evaluating multiple time points during a cell proliferation study.

Preliminary results from later time points (6, 12, and 18 months) confirmed the 3-month data and demonstrated that, over time, only 10 and 15 ppm formaldehyde caused increases in nasal cell proliferation. The concentration response in nasal cell proliferation correlated with the tumor response (*21*). These results strongly support the hypothesis that sustained increases in cell proliferation play a critical role in the carcinogenic process of formaldehyde (*21*). It is interesting to note that increases in cell proliferation were found in each site evaluated, including the medial aspect of the maxilloturbinate (Fig. 1). The number of tumors arising from this latter site was disproportionately lower as compared to the other sites at risk, even though LIs were approximately equivalent between sites. The lack of a correlation between cell proliferation and tumor induction at this site may be attributed to differences in regional susceptibility to formaldehyde-induced cancer, the small target area at risk (and therefore fewer target cells at risk), or other as yet unidentified factors.

## Summary

Cell death and renewal are prominent features of many toxicologic injuries to the nasal epithelium. Toxicant-induced cell necrosis followed by regeneration could, therefore, be a major determinant in chemical carcinogenesis in the nasal passages. Studies with formaldehyde have demonstrated a good correlation of concentration-dependent cellular injury, sustained

increased proliferation, and tumor formation. Because cell proliferation is clearly involved in chemical carcinogenesis, these dose-responsive changes represent potentially important data that might be used in setting chronic bioassay doses, understanding mechanism, and evaluating human risk. It should be stressed, however, that cell proliferation in response to cell death is not the sole determinant in nasal carcinogenesis because other inhaled irritant gases, such as dimethylamine, induce severe nasal cytotoxicity, inflammation, and squamous metaplasia, yet do not induce nasal tumors after chronic exposure (*22*). Additional work is needed to delineate the correlation between nasal toxic responses, epithelial proliferation, and the carcinogenic process.

## REFERENCES


1. Fabrikant, J. I., and Cherry, J. The kinetics of cellular proliferation in normal and malignant tissues. X. Cell proliferation in the nose and adjoining cavities. Ann. Otol. Rhinol. Laryngol. 79: 572–578 (1970).
2. Wells, A. B. The kinetics of cell proliferation in the tracheobronchial epithelium of rats with and without chronic respiratory disease. Cell Tissue Kinet. 3: 185–206 (1970).
3. Grisham, J. W., Kaufmann, W. K., and Kaufman, D.G. The cell cycle and chemical carcinogenesis. Surv. Pathol. Res. 1: 49–66 (1983).
4. Cotran, R. S., Kumar, V., and Robbins, S. L. Robbins Pathologic Basis of Disease. W. B. Saunders Co., Philadelphia, PA, 1989.
5. Monticello, T. M., Miller, F. J., and Morgan, K. T. Regional increases in rat nasal epithelial cell proliferation following acute and subchronic inhalation of formaldehyde. Toxicol. Appl. Pharmacol. 111: 409–421 (1991),
6. Morgan, K. T., and Monticello, T. M. Airflow, gas deposition, and lesion distribution in the nasal passages. Environ. Health Perspect. 88: 209–218 (1990).
7. Monticello, T. M., Morgan, K. T. and Hurtt, M. E. Unit length as the denominator for quantitation of cell proliferation in nasal epithelia. Toxicol. Pathol. 18: 24–31 (1990).
8. Monticello, T. M. Formaldehyde-induced pathology and cell proliferation. Ph.D. Dissertation, Duke University, Durham, NC, 1990.
9. Monticello, T. M., Renne, R., and Morgan, K. T. Chemically induced cell proliferation in upper respiratory tract carcinogenesis. In: Chemically Induced Cell Proliferation: Implications for Risk Assessment (B.E. Butterworth, T.J. Slaga, W. Farland, M. McClain, Eds.), Wiley Liss, New York, 1991, pp. 323–335.
10. Hecht, S. S., Chen, C. B., Ohmori, T., and Hoffman, D. Comparative carcinogenicity in F344 rats of the tobacco-specific nitrosamines, N'-nitrosonormicotine and 4-(N-methyl-N-nitrosamino)-1-(3-pyridyl)-1-butanone. Cancer Res. 40: 298–302 (1980).
11. Belinsky, S. A., Walker, V. E., Maronpot, R. R., Swenberg, J. A., and Anderson, M.W. Molecular dosimetry of DNA adduct formation and cell toxicity in rat nasal mucosa following exposure to the tobacco specific nitrosamine 4-(N-methyl-N-nitrosamino)-1-(3-pyridyl)-1-butanone and their relationship to induction of neoplasia. Cancer Res. 47: 6058–6065 (1987).
12. Goldsworthy, T. L., Monticello, T. M., Morgan, K. T., Bermudez, E., Wilson, D. M., Jackh, R., and Butterworth, B. E. Examination of potential mechanisms of carcinogenicity of 1,4-dioxane in rat nasal epthelial cells and hepatocytes. Arch. Toxicol. 65: 1–9 (1991).
13. NCI. Bioassay of Dioxane for Possible Carcinogenicity. National Cancer Institute, Carcinogenesis Technical Report Series, No. 80, Bethesda, MD, 1978.
14. Bogdanffy, M. S., Mazaika, T. J., and Fasano, W. J. Early cell proliferative and cytotoxic effects of phenacetin on rat nasal mucosa. Toxicol. Appl. Pharmacol. 98: 100–112 (1989).
15. Isaka, H., Yashii, H., Otsuji, A., Koike, M., Nagai, Y., Koura, M., Sugiyasu, J., and Kanabayashi, T. Tumors of Sprague-Dawley rats induced by long-term feeding of phenacetin. Jpn. J. Cancer Res. 70: 29–36 (1979).
16. Gross, E. A., Mellick, P., Kari, F., and Morgan, K. T. Histopathology and cell replication in the nasal epithelium of rats and mice exposed to glutaraldehyde vapor. Toxicologist 12: 399 (1992).
17. St. Clair, M. B. G., Gross, E. A., and Morgan, K. T. Pathology and cell proliferation induced by intra-nasal instillation of aldehydes in the rat: comparison of glutaraldehyde and formaldehyde. Toxicol. Pathol. 18: 353–361 (1990).
18. Kerns, W. D., Pavkov, K. L., Donofrio, D. J., Gralla, E. J., and Swenberg, J.A. Carcinogenicity of formaldehyde in rats and mice after long-term inhalation exposure. Cancer Res. 43: 4382–4392 (1983).
19. Ma, T.-H. and Harris, M. M. Review of genotoxicity of formaldehyde. Mutat. Res. 196: 37–59 (1988).
20. Morgan, K. T., Kimbell, J. S., Monticello, T. M., Patra, A. L., and Fleishman, A. Studies of inspiratory airflow patterns in the nasal passages of the F344 rat and rhesus monkey using nasal molds: relevance to formaldehyde toxicity. Toxicol. Appl. Pharmacol. 110: 223–240 (1991).
21. Monticello, T. M., Miller, F. J., Swenberg, J. A., Starr, T. B., Gibson, J. E., and Morgan, K. T. Association of enhanced cell proliferation and nasal cancer in rats exposed to formaldehyde. Toxicologist 12: 267 (1992).
22. Buckley, L. A., Morgan, K. T., Swenberg, J. A., James, R. A., Hamm, T. E., and Barrow, C. S. The toxicity of dimethlyamine in F-344 rats and $B6C3F_1$ mice following a 1-year inhalation exposure. Fundam. Appl. Toxicol. 5: 341–352 (1985).
23. Morgan, K.T., Jiang, X. Z., Starr, T. B., and Kerns, W. D. More precise localization of nasal tumors associated with chronic exposure of F-344 rats to formaldehyde gas. Toxicol. Appl. Pharmacol. 82: 264–271 (1986).