 Doi: 10.1111/j.1742-7843.2011.00755.x

Benzo[a]pyrene Exposure Increases Toxic Biomarkers and Morphological Disorders in Mouse Cervix

Meili Gao[1], Yongfei Li[2], Ying Sun[3], Walayat Shah[1,4], Shuiyun Yang[1], Yili Wang[1] and Jiangang Long[5]

[1]Institute of Cancer Research, Department of Biological Science and Engineering, The Key Laboratory of Biomedical Information Engineering of Ministry of Education, School of Life Science and Technology, Xi'an Jiaotong University, Xi'an, Shaanxi, China, [2]School of Materials and Chemical Engineering, Xi'an Technological University, Xi'an, Shaanxi, China, [3]School of Medicine, Xi'an Jiaotong University, Xi'an, Shaanxi, China, [4]Institute of Basic Medical Sciences, Khyber Medical University, Peshawar, Pakistan, and [5]Institute of Mitochondrial Biology and Medicine, Department of Biological Science and Engineering, The Key Laboratory of Biomedical Information Engineering of Ministry of Education, School of Life Science and Technology, Xi'an Jiaotong University, Xi'an, Shaanxi, China

(Received 1 March 2011; Accepted 25 May 2011)

Abstract: Benzo[a]pyrene (BaP) is a representative compound of polycyclic aromatic hydrocarbons exerting cytotoxicity and genotoxicity in the human liver, lung, stomach and skin. However, the toxic effect of BaP on cervical tissue remains unclear. This study was carried out to investigate the toxic effects of BaP on the cervix of ICR mice. Female mice were treated with BaP by intraperitoneal injection and oral gavage at a dose of 2.5, 5 and 10 mg/kg body-weight, twice a week for 14 weeks. BaP treatment caused a significant increase in the levels of MDA and IL-6 with significantly increased activity of CYP1A1, creatine kinase and aspartate aminotransferase (AST) and decreased activity of glutathione-*S*-transferase in the cervix and liver. The relative cervix weight was markedly reduced in the intraperitoneal BaP injection groups, whereas only a slight reduction was observed in the oral gavage groups. The increase in weight decreased with increasing BaP dose. Moreover, BaP treatment induced significant pathomorphological changes in the cervical tissue and increased the mortality of the mice. Taken together, these results suggest that BaP causes a certain toxic effect on cervical tissue.

Polycyclic aromatic hydrocarbons (PAHs) are by-products of any incomplete combustion of organic material and are present in the diet, the workplace and in the environment. Benzo[a]pyrene (BaP) is the representative compound of PAHs and a well-known carcinogen [1–3]. BaP is subject to biotransformation into radical cation and B*a*P-7, 8-diol-9, 10-epoxide (BPDE) by enzymes of the P450 system, especially cytochrome P4501A1 (CYP1A1). This procarcinogen epoxide derivation is the essential carcinogenic metabolite covalently bound to the guanine base of the DNA [4]. In addition, it can be catalysed by the enzyme dihydrodiol dehydrogenases into the reactive and redox-active BaP-7, 8-dione [5,6].

Reactive oxygen species (ROS) are also produced during the biotransformation of BaP [1,7]. Our defence against ROS damage is the enzymatic and non-enzymatic antioxidant defence systems that allow scavenging of ROS. Glutathione-*S*-transferase (GST) is an antioxidant enzyme that conjugates with reduced glutathione (GSH), an important reaction leading to the detoxification of xenobiotic reactivity [3]. Lipid peroxidation (LPO) can occur by exposure to various carcinogens including BaP and may be involved in cancer, ageing, neurodegenerative disease, malaria and arteriosclerosis as well as in other pathological events in living organisms [8].

It is now well-established that persistent cervical infection by high-risk human papillomavirus (HR-HPV) types is a major cause of cervical cancer. However, only a small fraction of HP-HPV-infected women develop cervical cancer, indicating that other co-factors may also be involved in this process. Cigarette smoking is the one among these co-factors. Epidemiological studies have implicated cigarette smoking as an independent risk factor for the development of cervical cancer, with odds ratios ranging from 1.8 to 4.3 [9,10]. Tobacco smoke is a complex mixture of at least 4000 different agents, and many of its ingredients, such as nicotine, cotinine, BaP and 4-(*N*-methyl-*N*-nitrosamino)-1-(3-pyridyl)-1-butanone, which are potent inducers of carcinogenesis, have been detected in the cervical mucus of women [11–14]. Topical application of BaP to the cervix induces squamous cell carcinoma in mice and hamsters [14,15]. However, the exact mechanism of BaP toxicity on cervical tissue is still not fully understood. The aim of this study was to investigate the toxic effects of BaP on biomarkers and morphological changes in cervical tissue of female ICR mice.

Materials and Methods

Chemicals. Benzo[a]pyrene (BaP, 98% purity) was purchased from Sigma (St. Louis, MO, USA). Aspartate aminotransferase (AST)

Author for correspondence: Meili Gao and Jiangang Long, Department of Biological Science and Engineering, The Key Laboratory of Biomedical Information Engineering of Ministry of Education, School of Life Science and Technology, Xi'an Jiaotong University, Xi'an, Shaanxi 710049, China (fax 086 029 82668463 411, e-mail gaomeili@mail. xjtu.edu.cn; jglong@mail.xjtu.edu.cn).

© 2011 The Authors
Basic & Clinical Pharmacology & Toxicology © 2011 Nordic Pharmacological Society

and creatine kinase (CK) kits were obtained from Jiangcheng Biological Co. Ltd., Nanjing, Jiangsu, China. Trichloroacetic acid (TCA), 2-thiobarbituric acid (TBA), GSH and 1-chloro-2, 6-dinitrobenzene were obtained from Promega (Madison, WI, USA). IL-6 immulite chemiluminescent enzyme immunometric assay was bought from Immulite; DPC, Los Angeles, CA, USA. All other reagents used were of analytical grade and purchased locally (China).

Animals and housing. Female ICR mice (18–22 g) were purchased from the Experimental Animal Center of Xi'an Jiaotong University, Shaanxi Province, China. The mice were kept in a cross-ventilated animal room at 22 ± 2°C, with relative humidity of 50–60%, and a 12-hr light/dark cycle with free access to conventional laboratory feed and water. The mice were acclimatized for at least 1 week before the beginning of experimental procedures. The experiments on animals were performed based on the animal ethics guidelines of the Institutional Animal Ethics Committee.

Experimental design. Benzo[a]pyrene was dissolved in sesame oil shortly before oral gavage or intraperitoneal injection. The animals were randomly divided into two groups: the intraperitoneal injection group and the oral gavage group. Each group was further divided into five subgroups: control, vehicle, low-dose BaP (2.5 mg/kg body-weight), middle-dose BaP (5 mg/kg body-weight) and high-dose BaP (10 mg/kg body-weight) subgroups. BaP was administered twice a week via intraperitoneal injection or oral gavage. The vehicle subgroup received an equal volume of sesame oil twice a week, and the control subgroup remained untreated until the termination of the experiment. For the determination of biomarkers of LPO, GST, CYP1A1, CK, AST and IL-6, 100 mice (10 mice × 10 subgroups) were enrolled. Another 260 mice (26 mice × 10 subgroups) were used for BaP-induced pathological study. The observation for biomarkers and pathological assays lasted for 14 weeks. Several mice died because of BaP treatment during the experimental period, so the number of mice in the groups was reduced to 10 or 26 to constitute equality.

Determination of LPO levels and GST activity. Lipid peroxidation was assayed according to the method of Wright *et al.* [16]. The reaction mixture, in a total volume of 1.0 mL, contained 0.58 mL phosphate buffer (0.1 M, pH 7.4), 0.2 mL tissue homogenate (10%, w/v), 0.2 mL ascorbic acid (100 mM) and 0.02 mL ferric chloride (100 mM) and was incubated at 37°C in a shaking water bath for 1 hr. The reaction was stopped by the addition of 1.0 mL TCA (10%, w/v), followed by the addition of 1.0 mL TBA (0.67%, w/v) and subsequent placement of all the tubes in a boiling water bath for 20 min. Finally, the tubes were shifted to an ice-bath and centrifuged at 2500 × *g* for 10 min. The optical density was measured at 532 nm by a spectrophotometer.

Glutathione-S-transferase activity was determined as described by Habig and Jakoby [17]. The reaction mixture contained 0.1 mol/L PBS (pH 6.5), 30 mM GSH, 30 mM 1-chloro-2, 6-dinitrobenzene and tissue homogenate. The optical density was measured at 340 nm by the spectrophotometer.

Determination of 7-ethoxyresorufin-O-deethylase (EROD) activity. The activity of the CYP1A1 enzyme was measured using the EROD activity. Briefly, individual cervical and hepatic tissues were homogenized in ice-cold solution (0.25 M sucrose, 0.1 M Tris–HCl, 1 mM EDTA, PH 7.4). The microsomal fraction was separated by ultracentrifugation, and the collected pellet was further dissolved with 1 mL of 20% glycerol solution (pH 7.4) containing 0.1 M Tris–HCl, 1 mM EDTA and 0.25 M sucrose. Microsomal EROD activity was determined by the method of Pohl and Fouts [18].

Detection of the activities of creatine kinase, aspartate aminotransferase and interleukin-6 (IL-6) levels assay. Creatine kinase and AST were measured with an assay kit according to the manufacturer's instructions. AST was determined based on the ability of the enzyme to form pyruvate, which reacts with 2, 4-dinitrophenylhydrazine in hydrochloric acid. The assay tube contained 0.1 mL sample and 0.5 mL matrix solution of AST (100 mM $K_2HPO_4 \cdot 3H_2O$, 100 mM KH_2PO_4, 200 mM aspartate, 2.0 mM α-ketoglutaric acid, 0.1% NaN_3). The tubes were incubated in a water back of 37°C for 1 hr. Then, 0.5 mL 2, 4-dinitrophenylhydrazine solution (100 mM HCl, 1.0 mM 2, 4- dinitrophenylhydrazine) was added and maintained at 37°C for 20 min. Finally, 5.0 mL 0.40 M NaOH was added at room temperature and kept for 10 min. Absorbance analysis was measured at 505 nm.

Creatine kinase activity was measured by an *N*-acetylcysteine (NAC)-activated kit. This is based on the ability of CK to form ATP, which reacts with glucose to produce glucose-6-phosphate (G-6-P), catalysed by hexokinase (HK). In the presence of G-6-P dehydrogenase (G-6-PDH), resultant G-6-P further reacts with $NADP^+$ to form NADPH. Briefly, the reaction mixture contained 8.0 μL sample, 320 μL R1 (containing 10 mM NADP, 2.5 mM ADP, 25 mM glucose, 3800 U/L HK, 1900 U/L G-6-PDH, 20 mM NAC). The tubes were maintained at 37°C for 5 min. Hereafter, 80 μL R2 (38 mM creatine phosphate disodium) was added and maintained at 37°C for 3 min. After 3 min., the CK activity was determined by the concentration of NADPH measured at 340 nm.

For the IL-6 protein concentration assay, cervical tissues were collected and homogenized immediately after centrifugation at 400 × *g* for 5 min. and the supernatant was retrieved. The blood samples were collected, and sera were prepared. Protein levels of IL-6 were expressed as picograms of cytokine per milligram of total protein (pg/mg protein). Protein concentrations of the supernatant were determined by the Bradford procedure [19] using bovine serum albumin as standard. Cytokine IL-6 protein analysis was performed employing an Immulite Automated Analyser (Diagnostic Products Corp., Los Angeles, CA, USA), using the commercially available immulite chemiluminescent enzyme immunometric assay according to the manufacturer's instructions.

Light microscopic examination of cervix. The tissue specimens were obtained from different doses of BaP-treated and control mice. Archival paraformaldehyde-fixed, paraffin-embedded blocks were retrieved, and serial sections of 5-μm thickness were prepared. The sections were deparaffinized by washing twice in xylene for 15 min. and twice in ethanol for 5 min. The tissue samples were stained with haematoxylin and eosin (H-E) for routine histopathological examination. All sections from the experimental animals were observed and photomicrographed under light microscope (Olympus BX-51, Tokyo, Japan) by two histologists blinded to the study.

Statistical analysis. All values are expressed as mean ± S.D. The analyses were performed with the SPSS 13.0 software package. The analysis of variance was applied for the comparison of the means of the different treatment groups. The data were processed by Dunnet's *post-hoc* test, and $p < 0.05$ was accepted as significant difference.

Results

Effects of BaP on body-weight, relative cervix weight and mortality.

Treatment of the mice with BaP produced a decrease in activity, appetite and body-weight and an increase in mortality. Mice mortality is shown in table 1. In the BaP-treated oral gavage subgroups, the mortality was 0%, 3.85% and 7.69%, respectively. In the intraperitoneal injection subgroups, the mortality was 3.85%, 11.54% and 15.38%, respectively.

The effects of BaP on body-weight of ICR mice are shown in fig. 1A,B. The initial body-weights were not significantly different among the experimental groups. The control body-

© 2011 The Authors

ED_006137A_00053006-00002

Table 1.
Effect of the pathomorphological changes in cervical uterine tissues of each subgroup induced by BaP.

Groups	Numbers[1]/(mortality %[2])	NE	EH	AH	IR[n]
I.p. injection					
Control	26 (0)	26	0	0	3
Vehicle control	26 (0)	25	1	0	4
2.5 mg/kg	25 (3.85)	19	5	1	11
5.0 mg/kg*	23 (11.54)	14	6	3	15
10 mg/kg*	22 (15.38)	10	7	5	18
Oral gavages					
Control	26 (0)	26	0	0	2
Vehicle control	26 (0)	26	0	0	3
2.5 mg/kg	26 (0)	22	4	0	10
5.0 mg/kg*	25 (3.85)	17	6	2	12
10 mg/kg*	24 (7.69)	13	7	4	18

I.p. injection, intraperitoneal injection; NE, normal epithelium; EH, epithelial hyperplasia; AH, atypical hyperplasia; IR[n], number of inflammatory response mice; BaP, benzo[a]pyrene.
[1]Number of animals using HE assay in treatment subgroups.
[2]Mortality of each group is shown as percentage in parenthesis.
*Significantly different from concurrent control group at $p < 0.05$.

weight was the highest at all stages after 3 weeks of treatment. The body-weight increased before 6 weeks and then decreased till the end of week 10 in the BaP-treated groups. In addition, the increase in body-weight decreased if the dose of BaP was increased.

As the initial body-weights and those of each week differed among the experimental groups (fig. 1A,B), cervix weight was expressed relative to body-weight (milligram per gram for the cervix), which is a more sensitive biomarker to measure cervix dysfunction. The effects of BaP on the relative cervix weight of ICR mice are shown in fig. 1C. The relative cervix weight decreased slightly in the oral gavage groups as well as in the low-dose BaP-treated intraperitoneal injection subgroup, while a significant decrease ($p < 0.05$) was observed in the middle-dose and high-dose intraperitoneal injection subgroups of the BaP-treated animals.

Effects of BaP on EROD and GST activities and MDA levels.
Figure 2 illustrates the effect of BaP on EROD and GST activities as well as MDA levels in cervix and liver of the oral gavage and intraperitoneal injection groups, respectively. The activity of EROD and MDA levels increased significantly and dose dependently ($p < 0.001$) in the BaP-treated groups compared with the control groups. Meanwhile, the activities of GST decreased significantly ($p < 0.05$, $p < 0.01$ and $p < 0.001$, respectively) in the BaP-treated groups compared with the concurrent controls. Additionally, GST activity decreased with increasing BaP dose.

Effects of BaP on CK and AST activities.
The effects of BaP on CK and AST activities in cervix and serum are depicted in fig. 3. BaP administration resulted in a significant elevation in CK and AST activities as compared to the concurrent control groups ($p < 0.05$, $p < 0.01$ and $p < 0.001$, respectively). Similar to the change in EROD activity, CK and AST activities were higher with increasing BaP dose.

Effects of BaP on pathological evaluation and IL-6 assay.
The effects of BaP-induced cervical injury were also apparent by histopathological examination. Figure 4 shows the HE-stained cervical epithelial tissue. In the control and vehicle control groups, cervical epithelium had normal architecture (fig. 4A). In the BaP-treated mice, pathomorphological changes, such as squamous epithelial metaplasia, cervical epithelial hyperplasia and atypical hyperplasia (fig. 4B–D), were exhibited in the cervix. Compared with the control groups (table 1), BaP exposure led to significant ($p < 0.05$) pathogenesis in cervical tissue but not in the groups treated with low-dose BaP. Inflammatory cells (fig. 4B–D) were also observed in the sections of BaP-treated mice. To further study the mechanism of BaP-induced inflammatory response, we assayed the concentrations of IL-6 protein in cervix and serum. The concentrations of IL-6 were significantly higher ($p < 0.05$, $p < 0.01$ and $p < 0.001$, respectively) in the BaP-treated groups *versus* the concurrent controls (fig. 3). In addition, partial fibrosis change in stroma was also observed (fig. 5B) in the BaP-treated groups as compared to normal cervical tissue in the control or vehicle groups (fig. 5A). The number of inflammatory response mice was increased with the increasing dose of BaP (table 1).

Discussion

Epidemiological reviews have addressed the risk factor or dependent factor of cigarette smoke exposure on cervical cancer [12]. However, the toxic effects of the important component of cigarette smoke (BaP) on biomarkers and on pathological changes in cervical tissue have not been studied extensively as yet. The purpose of the present investigation was to examine the changes in toxic biomarkers through the activities of CYP1A1, GST, AST, CK and the levels of LPO, IL-6 as well as the relative cervix weight of mice. Additionally, morphological changes of cervical tissue were examined on HE-stained sections by light microscopy.

© 2011 The Authors

ED_006137A_00053006-00003

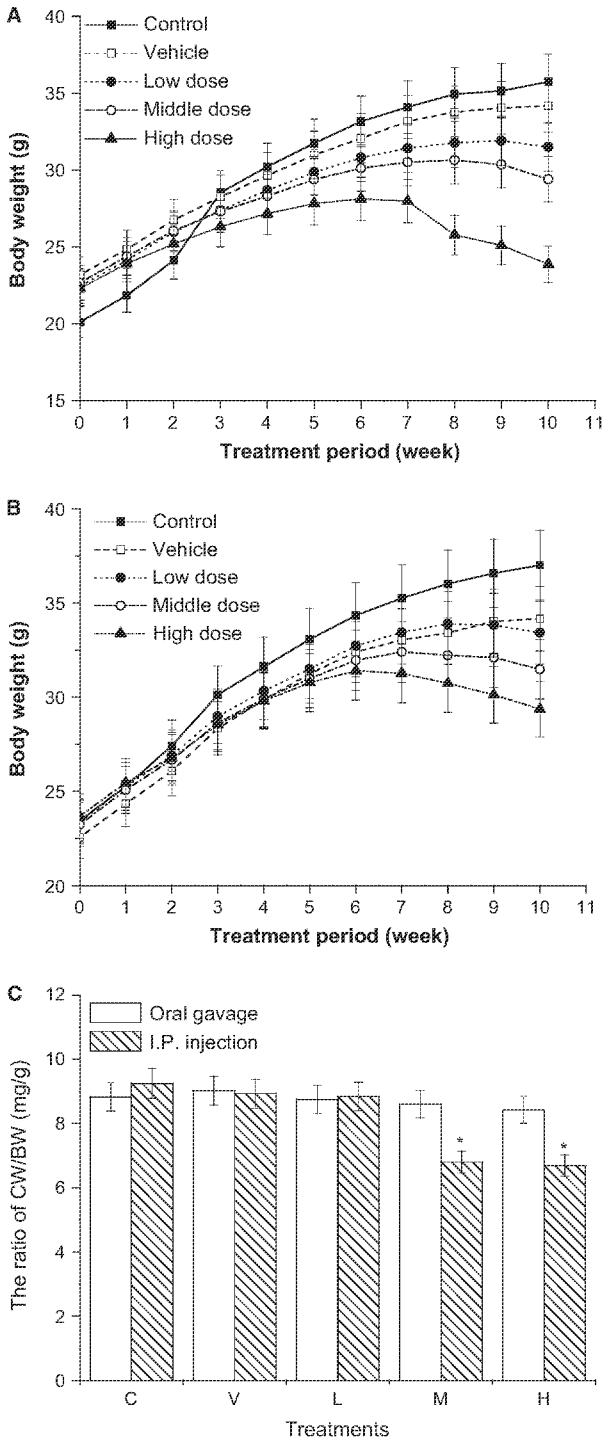

Fig. 1. Effects of benzo[a]pyrene (BaP) on body-weight and the relative cervix weight of the experimental groups. (A) Oral gavage, (B) Intraperitoneal injection. Each point represents the mean body-weight per mouse group. All measurements of body-weight from week 3 were significantly increased ($p < 0.05$) except for the high dose of oral administration at weeks 9 and 10 compared with concurrent controls, respectively. (C) ICR female mice were intraperitoneally injected or orally gavaged with BaP (L: low dose, 2.5 mg/kg; M: middle dose, 5 mg/kg; H: high dose, 10 mg/kg) twice a week for 14 weeks. C: control, untreated group; V: sesame oil group. I.p.: intraperitoneal. CW: cervix weight; BW: body-weight. Values are mean ± S.D., n = 7. *$p < 0.05$ *versus* concurrent control.

Comparison of body-weights between control and BaP-treated animals revealed that the body-weights of mice were affected by BaP. The findings imply that the increase rate of body-weight in mice is retarded by BaP. The likely explanation for this may be the neurotoxicity induced by BaP in the experimental groups. Several recent studies have reported inhibition of acetylcholinesterase and cholinesterases (ChE) after BaP exposure. This inhibition may have severe repercussions in functions determinant for the survival and performance of the organism, such as feeding, predator avoidance, swimming and survival to toxicant exposure [20–22]. Hence, mortality increases with increasing doses of BaP. These findings suggest that BaP caused injury to the mice, which is in agreement with previous studies.

The metabolic activation of BaP occurs through the dihydrodiol epoxide and the orthoquinone pathways. The initial BaP oxidations are catalysed by P450s of the *CYP1* gene family. The induction of the CYP1A1 enzymes in different tissues has been used as a biomarker indicative of toxicity by measurements of EROD activity [23,24]. In this study, EROD activity in the cervix was significantly increased during BaP treatment. This observation is in accordance with previous studies showing that BaP caused induction of CYP1A1 in other organs such as liver and lung [23,25].

Previous studies have reported that many kinds of intermediate metabolites as well as a great deal of ROS are produced in the process of biotransformation of PAHs including BaP, and this further induces oxidative damage through the significant increase in MDA level and carbonyl content [5–7]. LPO is a well-established biomarker of oxidative damage caused by ROS, which is cytotoxic and acts as a tumour promotor or a co-carcinogenic agent. The measurement of MDA provides a convenient index of LPO [6]. In the present study, higher levels of MDA were demonstrated in the BaP-treated groups as compared to the control groups, and the differences were statistically significant. These results indicate that BaP treatment caused oxidative damage and loss of membrane integrity [1,3,26]. It is well known that free radicals participate in BaP epoxidation and these probably caused the increased MDA excretion after BaP exposure. In our study, the content of MDA in the BaP-treated groups was higher than in the concurrent control groups, indicating that their cervixes suffered from serious oxidative damage.

Generally, GST plays a crucial role in the detoxification processes through the conjugation with GSH catalysing the endogenous substances and xenobiotics [27]. Our study demonstrated significantly low GST values in cervical tissue after BaP administration. A previous study showed that the inhibition of the GST activity below its basal level would promote the generation of ROS, with a cascade of effects on the functional and structural integrity of cells and organelle membranes [28]. This further reduced the capacity to detoxify BaP and increase the vulnerability to oxidative stress [2,29]. The results of LPO and GST are in accordance with the reports showing that in cervical cancer patients, increased oxidative stress leads to consumption and depletion of

© 2011 The Authors

ED_006137A_00053006-00004

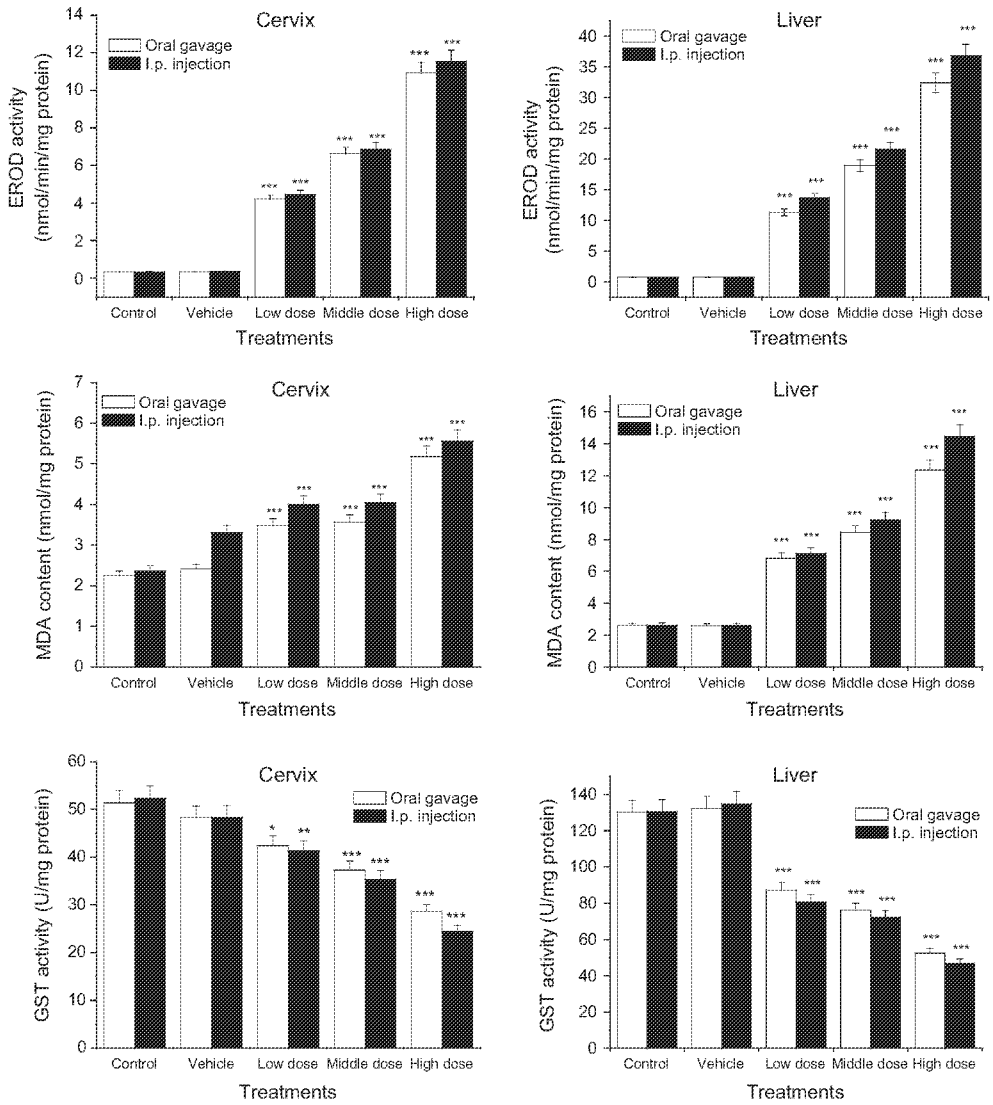

Fig. 2. The effects of benzo[a]pyrene (BaP) on CYP1A1 and glutathione-*S*-transferase activities and MDA contents in cervix and liver. ICR female mice were intraperitoneally injected and orally gavaged with BaP (2.5 mg/kg, low dose; 5 mg/kg, middle dose; 10 mg/kg, high dose, respectively) twice a week for 14 weeks. I.p.: intraperitoneal. Values are mean ± S.D., n = 7. $*p < 0.05$ *versus* concurrent control, $**p < 0.01$ *versus* concurrent control, $***p < 0.01$ *versus* concurrent control.

endogenous antioxidant enzymes such as SOD, CAT and GST [30,31].

We also assessed the clinical–chemical parameters including CK and AST in the cervix of BaP-treated mice. CK is an important enzyme of the aerobic metabolism of the cells that catalyses the conversion of creatine to phosphocreatine. AST can catalyse the reversible transfer of an amino group from aspartate to [α]-ketoglutarate to form glutamate and oxaloacetate. Our study shows that the activities of AST increased significantly in the BaP-treated groups as compared to the control groups. A study performed on Wistar rats noted increases in AST and ALT enzyme activities after BaP treatment [32], whereas another study performed on F-344 rats indicated no difference in AST activities between the control and BaP-treated groups [33]. In our study, AST changes are in accordance with the former study but differ from the latter one. Similarly, the activities of CK also increased significantly in the BaP-treated groups suggesting that CK activity was induced by BaP in cervical tissue. Scanty literature is available about the effects of BaP on the activities of AST and especially CK on cervical tissue, which needs to be evaluated further. On the other hand, some studies have suggested that an increase in CK and AST activities may correlate with the degree of endometritis in cows [34,35]. Therefore, we studied the inflammatory cell infiltration in the cervical tissue of BaP-treated mice, and then an inflammatory response was observed. The increase in inflammation appears to be responsible for the formation of ROS, DNA adduct during the metabolite of BaP and the induction of inflammatory chemokine, monocyte chemoattractant protein-1 (MCP-1) or other molecules [36–39]. To further investigate this inflammatory response, we measured the levels of

© 2011 The Authors

ED_006137A_00053006-00005

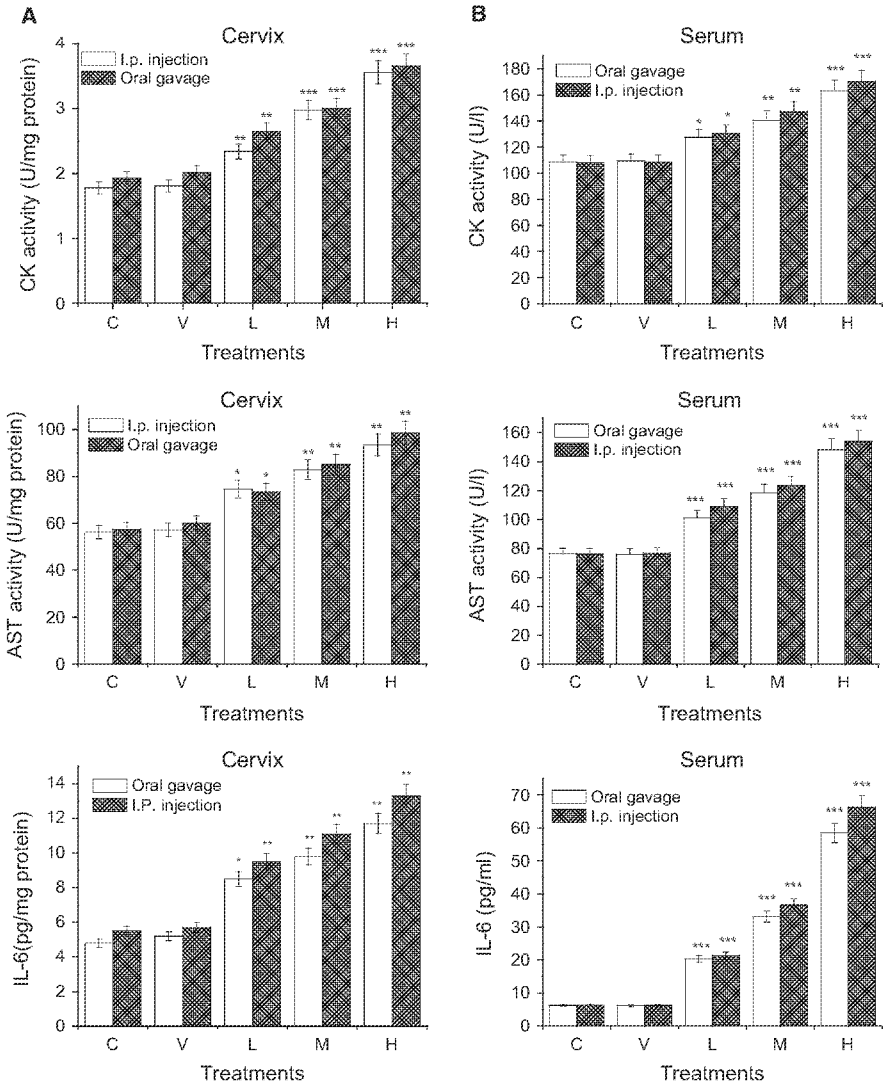

Fig. 3. The effects of benzo[a]pyrene (BaP) on creatine kinase (CK), aspartate aminotransferase (AST) activities and IL-6 levels in cervix and serum. ICR female mice were intraperitoneally injected and orally gavaged with BaP (L: low dose, 2.5 mg/kg; M: middle dose, 5 mg/kg; H: high dose, 10 mg/kg) twice a week for 14 weeks. C: control, untreated group; V: sesame oil group. I.p.: intraperitoneal. (A) CK activity. (B) AST activity. Values are mean ± S.D., n = 7. $*p < 0.05$ *versus* concurrent control, $**p < 0.01$ *versus* concurrent control, $***p < 0.01$ *versus* concurrent control.

pro-inflammatory cytokine IL-6. Higher levels of IL-6 were observed in the BaP-treated groups and may provide a pro-inflammatory potential to BaP in cervical tissues of the BaP-treated groups. Further studies on the inflammation associated with BaP in the cervical tissue may be necessary to fully understand the underlying pathways.

The toxic effects even as carcinogenesis of PAHs including BaP were induced in multiple organ sites [40] such as liver and lung. As previously described, BaP is subject to biotransformation into radical cation, the reactive and redox-active BaP-7, 8-dione, BPDE [4–6]. The significant increase in EROD activity, MDA content and the significant decrease in GST activity in liver further demonstrated that liver, as the significant metabolite site, is the central organ that plays a pivotal role in activation and elimination of toxic xenobiotics [41,42]. In the present study, BaP-induced hepatotoxicity was also expressed as a significant increase in the activities of AST and CK and the IL-6 levels in serum as reported in other studies [43,44].

In the light microscopic examination, a series of pre-cancerous lesions were observed in cervices of the BaP-treated groups, showing that BaP can cause different injuries to the cervical tissue epithelium. Furthermore, we also found a partial fibrosis change in stroma of cervical tissue in these groups. This finding is consistent with that of Yee *et al.* [45] who reported BaP-highlighting effects of inflammation and fibrosis. This might be due to the changes in LPO and the oxidative stress caused by BaP leading to fibrogenesis [46]. Regarding the relative cervix weight, we found a decrease in the ratio of cervix weight/body-weight. The decrease ratio is in line with the partial fibrosis in the stroma as this phenomenon also occurs in atrophic uterus [47]. Therefore, it is suggested that BaP may affect the function of cervix or cause the hypo-function of cervix [48].

© 2011 The Authors

ED_006137A_00053006-00006

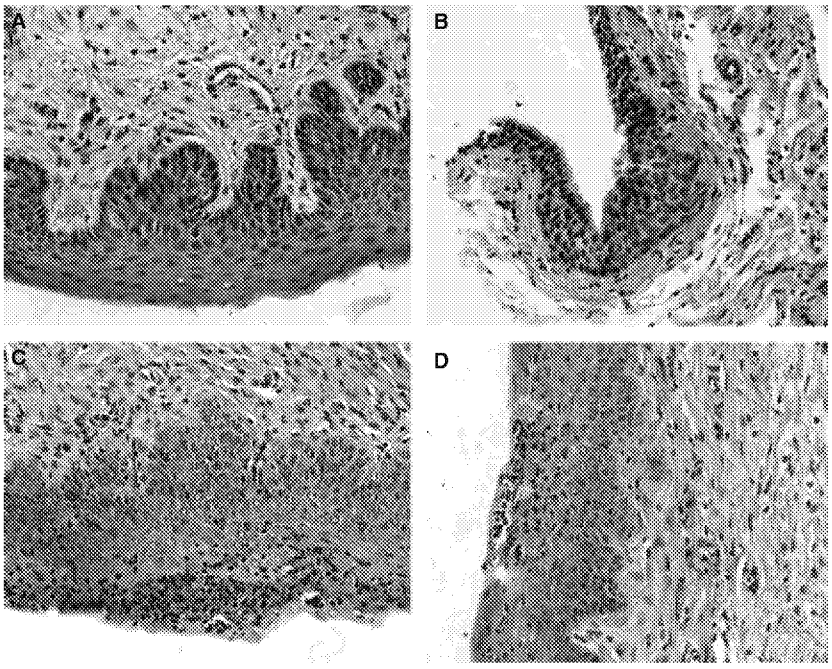

Fig. 4. Pre-cancerous lesions in cervical epithelium of mice induced by benzo[a]pyrene. By light microscopic examination (haematoxylin + eosin, magnification ×400): normal cervical epithelial tissue in controls (A), squamous epithelial metaplasia (B), cervical hyperplasia (C), atypical hyperplasia (D).

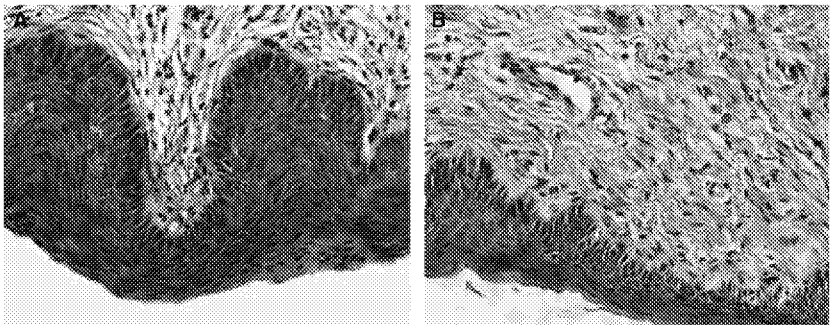

Fig. 5. Fibrosis changes of mouse cervical tissue induced by benzo[a]pyrene (BaP). By light microscopic examination (haematoxylin + eosin, magnification ×400): normal cervical epithelium tissue in control or vehicle control (A), representative image of fibrosis in cervix (B) observed in the tissue section from BaP-treated mice.

In summary, this study shows that prolonged BaP exposure to mice could adversely affect the cervical tissue through the increase in activities of CYP1A, CK and AST and in levels of LPO and IL-6 as well as the decrease in activities of GST and the relative cervix weight. The changes of these cervical biomarkers occurred accompanied by the toxic effect of BaP in liver, which has previously been well demonstrated. Moreover, pathomorphological changes and the decrease in body-weight also provide new evidence for the toxic effects of BaP. As BaP is a main carcinogenic and mutagenic component of tobacco smoke, the results in this study partially support the epidemiological studies, which closely correlate the relationship of cigarette smoke as a co-factor or risk factor for the development of cervical cancer.

Acknowledgements

This study was financially supported by a Principal grant of Xi'an Jiaotong University of China (7114003, 01380005) and National Natural Science Foundation of China (30700720).

References

1 Kim HS, Kwack SJ, Lee BM. Lipid peroxidation, antioxidant enzymes, and benzo[a]pyrene-quinones in the blood of rats treated with benzo[a]pyrene. Chem Biol Interact 2000;**127**:139–50.

2 Wu Y, Wang C, Wang Y, Zhao Y, Chen Y, Zuo Z. Antioxidant responses to benzo[a]pyrene, tributyltin and their mixture in the spleen of *Sebasticus marmoratus*. J Environ Sci 2007;**19**:1129–35.

3 Wang C, Zhao Y, Zheng R, Ding X, Wei W, Zuo Z. Effects of tributyltin, benzo[a]pyrene, and their mixture on antioxidant

© 2011 The Authors

ED_006137A_00053006-00007

defense systems in *Sebastiscus marmoratus*. Ecotoxicol Environ Saf 2006;**65**:381–7.
4 Armstrong SA, Wiele TV, Germida JJ, Siciliano SD. Aryl hydrocarbon bioaccessibility to small mammals from arctic plants using in vitro techniques. Environ Toxicol Chem 2007;**26**:491–6.
5 Tang DW, Chang KW, Chi CW, Liu TY. Hydroxychavicol modulates benzo[*a*]pyrene-induced genotoxicity through induction of dihydrodiol dehydrogenase. Toxicol Lett 2004;**152**:235–43.
6 Vieira LR, Sousa A, Frascoa MF, Lima I, Morgado F, Guilhermino L. Acute effects of benzo[a]pyrene, anthracene and a fuel oil on biomarkers of the common goby *Pomatoschistus microps* (Teleostei, Gobiidae). Sci Total Environ 2008;**395**:87–100.
7 Pan LQ, Ren J, Liu J. Responses of antioxidant systems and LPO level to benzo(a)pyrene and benzo(k)fluoranthene in the haemolymph of the scallop *Chlamys Ferrari*. Environ Pollut 2006; **141**:443–51.
8 Oost RV, Beyer J, Vermeulen NP. Fish bioaccumulation and biomarkers in environmental risk assessment: a review. Environ Toxicol Pharmacol 2003;**13**:149–57.
9 Harris TG, Kulasingam SL, Kiviat NB, Mao C, Agoff SN, Feng Q *et al.* Cigarette smoking, oncogenic human papillomavirus, Ki-67 antigen, and cervical intraepithelial neoplasia. Am J Epidemiol 2004;**159**:834–42.
10 Holschneider CH, Baldwin RL, Tumber K, Aoyama C, Karlan BY. The fragile histidinetriad gene: a molecular link wetween cigarette smoking and cervical cancer. Clin Cancer Res 2005;**11**:5756–63.
11 Alam S, Conway MJ, Chen HS, Meyers C. The cigarette smoke carcinogen benzo[*a*]pyrene enhances human papillomavirus synthesis. J Virol 2008;**10**:53–8.
12 Odongua N, Chae YM, Kim MR, Yun JE, Jee SH. Associations between smoking, screening, and death caused by cervical cancer in Korean women. Yonsei Med J 2007;**48**:192–200.
13 Eppel W, Worda C, Frigo P, Manavi M, Czerwenka K. The influence of cotinine on interleukin 6 expression in smokers with cervical preneoplasia. Acta Obstet Gynecol Scand 2000;**79**:1105–11.
14 Melikian AA, Sun P, Prokopczyk B, El-Bayoumy K, Hoffmann D, Wang X *et al.* Identification of benzo[a]pyrene metabolites in cervical mucus and DNA adducts in cervical tissues in humans by gas chromatography mass spectrometry. Cancer Lett 1999; **146**:127–34.
15 Näslund I, Rubio CA, Auer GU. Nuclear DNA changes during pathogenesis of squamous carcinoma of the cervix in 3, 4-benzopyrene-treated mice. Anal Quant Cytol Histol 1987;**9**:411–8.
16 Wright JR, Colby HD, Miles PR. Cytosolic factors which affect microsomal lipid peroxidation in lung and liver. Arch Biochem Biophys 1981;**206**:296–304.
17 Habig WH, Jakoby WB. Assays for differentiation of glutathione-Stransferase. Methods Enzymol 1981;**77**:398–405.
18 Pohl RJ, Fouts JR. A rapid method for assaying the metabolism of 7-ethoxyresorufin by microsomal subcellular fraction. Anal Biochem 1980;**107**:150–5.
19 Bradford MM. A rapid and sensitive method for quantitation of microgram quantities of protein utilizing the principle of protein-dye-binding. Anal Biochem 1976;**72**:248–54.
20 Moreira SM, Moreira-Santos M, Ribeiro R, Guilhermino L. The 'coral bulker' fuel oil spill on the north coast of portugal: spatial and temporal biomarker responses in mytilus galloprovincialis. Ecotoxicology 2004;**13**:619–30.
21 Zapata-Pérez O, Ceja-Moreno V, Domínguez J, Del Río-Garcia M, Rodríguez-Fuentes G, Chan E. Biomarkers and pollutants in the tilapia *Oreochromis Niloticus* in four lagoons from Reforma, Chiapas, Mexico: a case study. Mar Environ Res 2004; **58**:319–28.
22 Barsiene J, Lehtonen K, Koehler A, Broeg K, Vuorinen PJ, Lang T. Biomarker responses in flounder (*Platichthys flesus*) and mussel (*Mytilus edulis*) in the Klaipeda-Butinge area (Baltic Sea). Mar Pollut Bull 2006;**53**:422–36.
23 Kangl HG, Jeong SH, Cho MH, Cho JH. Changes of biomarkers with oral exposure to benzo(a)pyrene, phenanthrene and pyrene in rats. J Vet Sci 2007;**8**:361–8.
24 Spink DC, Wu SJ, Spink BC, Hussain MM, Vakharia DD, Pentecost B. Induction of CYP1A1 and CYP1B1 by benzo(*k*)fluoranthene and benzo(*a*)pyrene in T-47D human breast cancer cells: roles of PAH interactions and PAH metabolites. Toxicol Appl Pharmacol 2008;**226**:213–24.
25 Jin N, Zhu Y, Zhou J, Mao L, Zhao R, Fang T. Preventive effects of quercetin against benzo[a]pyrene-induced DNA damages and pulmonary precancerous pathologic changes in mice. Basic Clin Pharmacol Toxicol 2006;**98**:593–8.
26 Gao ML, Long JG, Li YF, Shah W, Fu L, Liu JK *et al.* Mitochondrial decay is involved in BaP-induced cervical damage. Free Radic Biol Med 2010;**49**:1735–45.
27 Dasgupta T, Hebbel RP, Kaul DK. Protective effect of arginine on oxidative stress in transgenic sickle mouse models. Free Radic Biol Med 2006;**41**:1771–80.
28 Deleve LD, Wang X, Kuhlenkamp JF, Kaplowitz N. Toxicity of azathioprine and monocrotaline in murine sinusoidal endothelial cells and hepatocytes: the role of glutathione and relevance to hepatic venoocclusive disease. Hepatology 1996;**23**:589–99.
29 Myllynen P, Kurttila T, Vaskivuo L, Vähäkangas K. DNA damage caused by benzo(a)pyrene in MCF-7 cells is increased by verapamil, probenecid and PSC833. Toxicol Lett 2007;**169**:3–12.
30 Sharma A, Rajappa M, Saxena A, Sharma M. Antioxidant status in advanced cervical cancer patients undergoing neoadjuvant chemoradiation. Br J Biomed Sci 2007;**64**:23–7.
31 Beevi SS, Rasheed MH, Geetha A. Evidence of oxidative and nitrosative stress in patients with cervical squamous cell carcinoma. Clin Chim Acta 2007;**375**:119–23.
32 Yang G, Fang Z, Liu Y, Zhang H, Shi X, Ji Q. Protective effects of Chinese traditional medicine buyang huanwu decoction on myocardial injury. http://ecam.oxfordjournals.org/ doi: 10.1093/ecam/nep013 (last accessed on 08 February 2009).
33 Knuckles ME, Inyang F, Ramesh A. Acute and subchronic oral toxicities of benzo[a]pyrene in F-344 rats. Toxicol Sci 2001; **61**:382–8.
34 Sattler T, Fürll M. Creatine kinase and aspartate aminotransferase in cows asindicators for endometritis. J Vet Med A Physiol Pathol Clin Med 2004;**51**:132–7.
35 Azawi OI, Omran SN, Hadad JJ. A study of endometritis causing repeat breeding of cycling iraqi buffalo cows. Reprod Domest Anim 2008;**43**:735–43.
36 Rojas M, Godschalk R, Alexnadrov K, Cascorbi I, Kriek E, Ostertag J. Myeloperoxidase-463A variant reduces benzo[a]pyrene diol epoxide DNA adduct in skin of coal tar treated patients. Carcinogenesis 2001;**22**:1015–8.
37 Güngör N, Roger WL, Pachen DM, Van Schooten FJ, Knaapen AM. Activated neutrophils inhibit nucleotide excision repair in human pulmonary epithelial cells: role of myeloperoxidase. FASEB J 2007;**21**:2359–67.
38 Oesterling E, Toborek M, Hennig B. Benzo[a]pyrene induces intercellular adhesion molecule-1 through a caveolae and aryl hydrocarbon receptor mediated pathway. Toxicol Appl Pharmacol 2008;**232**:309–16.
39 Kummer V, Mašková J, Matiašovic J, Faldyna M. Morphological and functional disorders of the immature rat uterus after postnatal exposure to benz[a]anthracene and benzo[k]fluoranthene. Environ Toxicol Pharmacol 2009;**27**:253–8.
40 Topinka J, Schwarz LR, Kiefer F, Wiebel FJ, Gajdos O, Vidova P *et al.* DNA adduct formation in mammalian cell cultures by polycyclic aromatic hydrocarbons (PAH) and nitro-PAH in coke oven emission extract. Mutat Res 1998;**419**:91–105.

© 2011 The Authors

ED_006137A_00053006-00008

41 Singh SV, Varma V, Zimniak P, Srivastava SK, Marynowski SW, Desai D *et al.* Structural basis for catalytic differences between alpha class human glutathione transferases hGSTA1-1 and hGSTA2-2 for glutathione conjugation of environmental carcinogen benzo[a]pyrene – 7, 8- diol – 9, 10- epoxide. Biochemistry 2004;**43**:9708–15.

42 Hesse S, Jernstrom B, Martinez M, Guenthner T, Orrenius S, Christodoulides L *et al.* Inhibition of binding of benzo(a)pyrene metabolites to nuclear DNA by glutathione and glutathione *S*-transferase B. Biochem Biophys Res Commun 1980;**94**:612–7.

43 Lakshmi B, Ajith TA, Jose N, Janardhanan KK. Antimutagenic activity of methanolic extract of *Ganoderma lucidum* and its effect on hepatic damage caused by benzo[a]pyrene. J Ethnopharmacol 2006;**107**:297–303.

44 Mirsadraee M, Shirdel A, Roknee F. Typhoid myopathy or typhoid hepatitis: a matter of debate. Indian J Med Microbiol 2007;**25**:351–3.

45 Yee H, Yie TA, Goldberg J, Wong KM, Rom WN. Immunohistochemical study of fibrosis and adenocarcinoma in domaint-negative p53 transgenic mice exposed to chrysotile asbestos and benzo(a)pyrene. J Environ Pathol Toxicol Oncol 2008;**27**:267–76.

46 Yamabe N, Yokozawa T. Protective effect of Hachimi-jio-gan against the development of pancreatic fibrosis and oxidative damage in Otsuka Long-Evans Tokushima Fatty rats. J Ethnopharmacol 2007;**113**:91–9.

47 Kauffold J, Melzer F, Berndt A, Hoffmann G, Hotzel H, Sachse K. Chlamydiae in oviducts and uteri of repeat breeder pigs. Theriogenology 2006;**66**:1816–23.

48 Miller KP, Borgeest C, Greenfeld C, Tomic D, Jodi A. Flaws in utero effects of chemicals on reproductive tissues in females. Toxicol Appl Pharmacol 2004;**198**:111–31.

© 2011 The Authors
Basic & Clinical Pharmacology & Toxicology © 2011 Nordic Pharmacological Society. *Basic & Clinical Pharmacology & Toxicology*